

Adding Chloroquine to Conventional Treatment for Glioblastoma Multiforme

A Randomized, Double-Blind, Placebo-Controlled Trial

Julio Sotelo, MD; Eduardo Briceño, MD; and Miguel Angel López-González, MD

Background: Malignant cell clones resistant to chemotherapy and radiotherapy frequently lead to treatment failure in patients with glioblastoma multiforme. Preliminary studies suggest that adding chloroquine to conventional therapy may improve treatment outcomes.

Objective: To examine the effect of adding chloroquine to conventional therapy for glioblastoma multiforme.

Design: Randomized, double-blind, placebo-controlled trial.

Setting: National Institute of Neurology and Neurosurgery of Mexico.

Patients: 30 patients with surgically confirmed glioblastoma confined to 1 cerebral hemisphere, with a Karnofsky performance score greater than 70, no comorbid disease, and age younger than 60 years.

Interventions: Oral chloroquine at 150 mg/d for 12 months beginning on postoperative day 5 or placebo. All patients received conventional chemotherapy and radiotherapy.

Measurements: Primary outcome was survival after surgery; surviving patients were followed up to October 2005. Periodic evaluation using the Karnofsky scale and imaging studies, as well as

hematologic tests and ophthalmologic examinations, was done in all patients.

Results: Median survival after surgery was 24 months for chloroquine-treated patients and 11 months for controls. At the end of the observation period, 6 patients treated with chloroquine had survived 59, 45, 30, 27, 27, and 20 months, respectively; 3 patients from the control group had survived 32, 25, and 22 months, respectively. Although not statistically significantly different, the rate of death with time was approximately half as large in patients receiving chloroquine as in patients receiving placebo (hazard ratio, 0.52 [95% CI, 0.21 to 1.26]; $P = 0.139$).

Limitations: The observed advantage of chloroquine may be due to chance; differences in pretreatment characteristics and conventional treatment regimens could not be adjusted for because of the small sample size.

Conclusions: Chloroquine may improve mid-term survival when given in addition to conventional therapy for glioblastoma multiforme. These results suggest that larger, more definitive studies of chloroquine as adjuvant therapy for glioblastoma are warranted.

Ann Intern Med. 2006;144:337-343.

For author affiliations, see end of text.

ClinicalTrials.gov Identifier: NCT00224978

www.annals.org

Despite numerous advances in the diagnosis of glioblastoma multiforme, there have been relatively few advances in therapy, and the prognosis of patients with this disorder has not changed considerably during the past decades. Recent studies have shown that median survival after aggressive treatment combining surgery, radiotherapy, and chemotherapy is approximately 1 year (1–4). Even the most sophisticated approaches, such as stereotactic radiosurgery, have failed to improve survival or quality of life (5). There are 2 main reasons that explain the high rate of therapeutic failure: the infiltrative nature of glioblastoma multiforme and the presence of cancer cells resistant to radiotherapy and chemotherapy. The latter might be due to the unrestricted growth of resistant cell clones within the original tumor, which replace those cells initially susceptible, or to the emergence of new mutant cell clones resistant to the treatment. This phenomenon could be prompted by the high rate of mutagenesis of malignant glial cells, which is increased by both ionizing radiation and antineoplastic drugs (1, 2, 4, 6).

Antimalarial drugs, particularly chloroquine and quinacrine, are strong DNA-intercalating agents and are lysosomotropic; both actions in eukaryotic cells modify several cell functions. In cells with a high mitotic rate, such as cancer cells, chloroquine and quinacrine are antimutagenic

(7, 8); however, they are not cytotoxic or antimetabolic and do not exhibit a substantial antineoplastic effect (9). In cultured glioma cells and in malignant glioma in rats, we have shown that these substances have a strong potentiating effect on the antineoplastic action of carmustine and maintain the long-term susceptibility of malignant glioma cells to chemotherapy (10). On the basis of these experimental findings, we conducted a preliminary, open-label trial on patients with glioblastoma multiforme by administering chloroquine in addition to surgery and to the standard courses of radiotherapy and chemotherapy; when compared with concurrent controls, survival was statistically significantly longer in chloroquine-treated patients (6). After that initial experience, we conducted the present

See also:

Print

Editors' Notes	338
Editorial comment	371
Summary for Patients	I-31

Web-Only

Conversion of figures and table into slides

Context

The median survival for patients with glioblastoma multiforme is 1 year despite aggressive treatment. Chloroquine interferes with cellular mechanisms that might cause treatment resistance.

Content

In this single-center, randomized, double-blind, placebo-controlled trial, 30 patients receiving surgery, chemotherapy, and radiotherapy for glioblastoma multiforme were randomly assigned to receive chloroquine or placebo for 12 months. Median survival was 24 months for patients who received chloroquine and 11 months for patients who received placebo. No patient stopped therapy because of toxicity.

Limitations

The number of patients was small, and the difference in survival was not statistically significant ($P = 0.139$).

Implications

Chloroquine, in conjunction with other treatments, may prolong survival in patients with glioblastoma multiforme. Larger clinical trials are needed.

—The Editors

double-blind, placebo-controlled study of chloroquine as adjuvant therapy for patients with glioblastoma multiforme.

METHODS**Patient Recruitment, Enrollment, and Follow-up**

During a 40-month period (October 2000 to January 2004), 120 patients with clinical suspicion of a malignant brain tumor were screened at the National Institute of Neurology and Neurosurgery of Mexico. Of these patients, 30 participated in the present study. All patients fulfilled the following inclusion criteria: glioblastoma multiforme, which was confirmed by 2 independent pathologists on the histologic specimen obtained at surgery; fair clinical neurologic status with a Karnofsky performance score of 70 or higher at the time of diagnosis; absence of associated severe disorders, such as diabetes and hypertension; evidence on magnetic resonance imaging (MRI) scans that the tumor was restricted to 1 hemisphere of the brain; and age younger than 60 years.

Intervention

All patients participating in the study received the same conventional scheme of chemotherapy and radiotherapy: extensive tumor ablation by surgery; 4 courses of carmustine at 200 mg/m², one given every 5 weeks and the first given 8 weeks after surgery; and radiotherapy that began 3 weeks after surgery, for a total radiation dose of 60 Gy (6000 rads) separated in 30 to 32 courses with daily

fractionated doses. All patients and their legal guardians signed the informed consent document, clearly stating their willingness to participate in a randomized, double-blind, placebo-controlled trial. Chloroquine tablets (Aralen, Sanofi-Synthelabo, Mexico City, Mexico), 150 mg, were commercially purchased, and identical placebo tablets were formulated; treatments were randomly distributed into 15 chloroquine and 15 placebo sets (each set was designed for 1-year treatment) and were coded at the laboratory of an independent investigator at another institution. We received the 30 sets coded and numbered, and they were administered in sequential order as the patients entered the trial. The study monitor sealed and kept the code until the end of the study. Therefore, the participants, those administering the treatment, and those assessing the outcomes were blinded to group assignment.

Chloroquine was administered at 150 mg/d, starting on day 5 after surgery, and was continued for 12 months; in a nontrial setting, chemotherapy and radiotherapy would have been completed before 12 months had passed. The dose of chloroquine used in this study was selected on the basis of several pharmacologic studies on toxicity, long-term administration, and antimalarial effectiveness (6, 7); it is also identical to the dose used in our preliminary study (6). The assignment of treatments was decodified in January 2005, when all patients had had surgery at least 1 year previously, and the follow-up continued until October 2005. Our institutional review board of research and the institutional board of ethics both approved the study. This study complied with the Consolidated Standards for Reporting Trials (CONSORT) items for a randomized trial (11).

Primary and Secondary Outcomes

Clinical evaluation after hospital discharge was done every 2 weeks, and MRI studies were done every 2 months. Tumor size was measured on the MRI scan taken before surgery; the largest diameter of the tumor on the axial planes was considered as a single value. Primary outcome was survival after surgery. Karnofsky score was determined at the time of diagnosis, 1 month after surgery, and 5 months after surgery. Signs of systemic toxicity induced by the therapy were studied monthly by routine analysis of peripheral blood, which included hematic biometry, blood chemistry, and hepatic tests. In addition, potential signs of drug toxicity in the retina as a result of chloroquine treatment were monitored monthly by ophthalmoscopic evaluation in all patients.

Statistical Analysis

Kaplan–Meier survival curves were plotted. Survival times in the 2 groups were compared by using the hazard ratio and 95% CI from a bivariate Cox regression. Statistical significance was assessed with the log-rank test. Other statistical comparisons were made by using the unpaired *t*-test and the Fisher exact test (SPSS, version 10.0, SPSS Inc., Chicago, Illinois).

Table. Characteristics of Patients with Glioblastoma Multiforme

Variable	Chloroquine Group (n = 15)	Placebo Group (n = 15)
Mean age (SD), y	40.8 (11.8)	46.1 (12.7)
Men/women, n/n	9/6	8/7
Mean tumor diameter before surgery (SD), mm	49.1 (13.8)	44.5 (9.0)
Mean duration of symptoms before surgery (SD), mo	5.5 (6.6)	3.7 (4.4)
Mean preoperative Karnofsky score (SD)	81.3 (9.9)	82.7 (11.6)
Mean 1-month postoperative Karnofsky score (SD)	81.3 (12.8)	82.7 (11.6)
Mean 5-month postoperative Karnofsky score (SD)	84.2 (10.7)	83.3 (13.1)
Conventional radiotherapy, n (%)	15 (100)	15 (100)
Conventional chemotherapy, n (%)	15 (100)	15 (100)
Clinical signs before surgery, n (%)		
Headache	12 (80)	10 (67)
Seizures	8 (53)	7 (47)
Nausea	7 (47)	7 (47)
Vomiting	6 (40)	5 (33)
Mental disturbances	4 (27)	3 (20)
Papilledema	5 (33)	3 (20)
Paresis	2 (13)	7 (47)
Diplopia	0	2 (13)
Hypoesthesia	1 (7)	0

Role of the Funding Source

This work was conducted at the National Institute of Neurology and Neurosurgery of Mexico, which is a public institution without any commercial interests. Partial support was obtained by a grant from Consejo Nacional de Ciencia y Tecnología (CONACyT), which is the federal agency for support of scientific research in Mexico. The agency did not participate in the design, conduct, analysis, or reporting of this study. No pharmaceutical companies participated in any part of the study.

RESULTS

Patient Characteristics and Follow-up

In the chloroquine group, the duration of symptoms and the diameter of the tumor were greater but the average age of the patients was slightly lower than in the placebo group; otherwise, the characteristics of patients were similar in the 2 groups (Table). Maximum, minimum, and median follow-ups were 59, 5, and 15 months, respectively. Radiotherapy or chemotherapy was not stopped in any surviving patient during the study period.

Survival

Median survival over the entire study period was 24 months for the patients in the chloroquine-treated group and 11 months for controls. At the end of the observation period, 6 patients (40%) from the chloroquine-treated group and 3 patients from the control group (20%) were still alive (Figure 1).

Secondary Outcomes

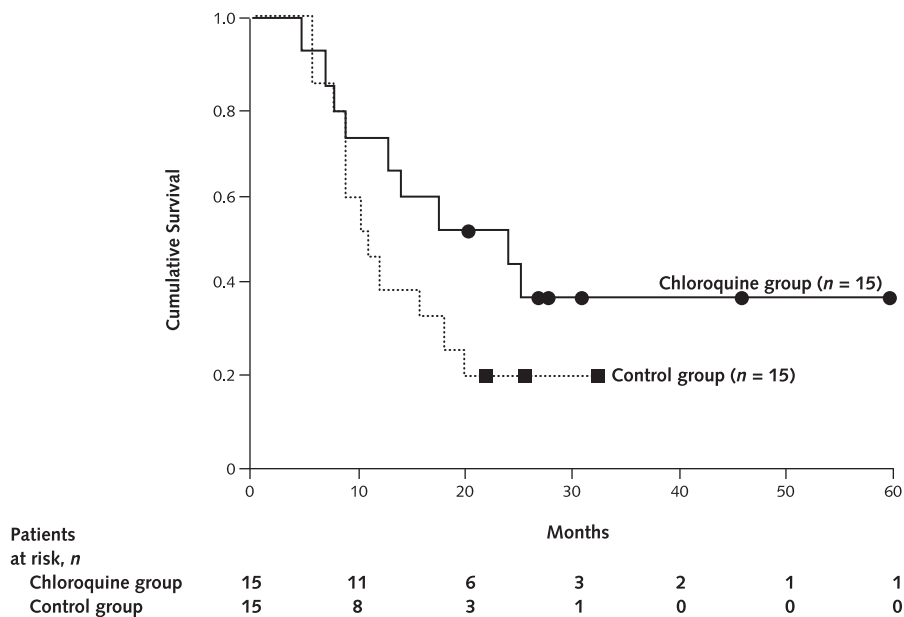
In October 2005, 6 patients from the chloroquine-treated group were alive. Of these, 1 had survived 59 months after surgery (Figure 2); 1 patient each had survived 45, 30, and 20 months, respectively, and 2 additional patients had survived 27 months. The patients from the

control group had survived 32, 25, and 22 months, respectively. Although not statistically significantly different, the rate of death over time was approximately half as large in patients receiving chloroquine as in patients receiving placebo (hazard ratio, 0.52 [95% CI, 0.21 to 1.26]; $P = 0.139$). The observed data are consistent with proportional hazards assumption ($P = 0.92$).

Adverse Events

During the trial, no signs of retinopathy related to chloroquine toxicity were found in any patient. Follow-up hematologic results were similar between chloroquine-treated patients and control patients (results not shown); however, at the analysis done 8 months after the beginning of treatment, mean values of leukocytes and platelets were lower in patients from the chloroquine-treated group (7.5×10^9 cells/L vs. 9.9×10^9 cells/L [$P = 0.072$] and 170×10^9 cells/L vs. 219×10^9 cells/L [$P = 0.055$], respectively). These variables were again similar 1 month later. No other secondary reactions attributable to the treatment were detected during the trial. Nonetheless, no patients stopped receiving chemotherapy or radiotherapy or were excluded from the experimental blinded therapy because of treatment-related adverse reactions. No patient from either group discontinued treatment or was lost to follow-up. According to the common toxicity criteria from the National Cancer Institute (12), toxicity by chloroquine in this trial was graded 0 to 1 (absent or minimal) in bone marrow cellularity. During follow-up, 2 patients from the chloroquine-treated group (13%) and 4 patients from the control group (27%) had seizures that were adequately controlled with antiepileptic drugs; these events were considered secondary to the neoplasm rather than a complication of therapy in all patients.

Figure 1. Kaplan–Meier estimates of survival in 30 patients with glioblastoma multiforme who received chloroquine ($n = 15$) or placebo ($n = 15$) in addition to conventional therapy.



At the end of the observation period, 6 patients from the chloroquine-treated group and 3 patients from the control group survived.

DISCUSSION

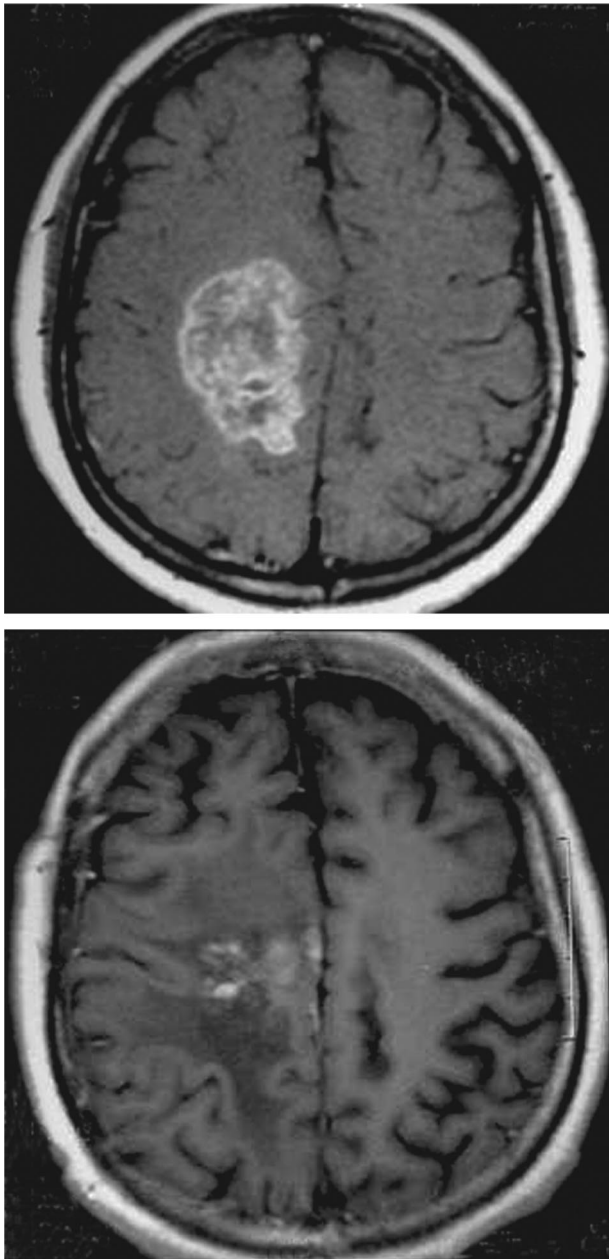
The addition of chloroquine to the conventional therapeutic approach for glioblastoma multiforme may increase mid-term survival; however, this figure is higher in our study than that obtained recently with novel chemotherapeutic agents (13). The inclusion criteria and treatment of patients who participated in the current study were identical to those of the 18 patients in our preliminary open-label study of glioblastoma multiforme (6). The results of both studies were similar and support a mid-term beneficial effect of chloroquine in the treatment of this disorder. Chloroquine is not a cytotoxic substance, and a well-described, relevant antineoplastic effect does not exist. Therefore, we speculate that the mechanisms for this effect on therapy could involve either the enhancement of cytotoxicity induced by conventional treatments or the prevention of mutagenicity in neoplastic cells, which maintain their susceptibility to radiotherapy and chemotherapy by allowing them to elude the appearance of resistant cell clones.

Few other substances besides chloroquine have shown substantial effects on intracellular signaling events and cellular functions while lacking cytotoxicity; several studies of chloroquine have failed to show an effect on cell growth or clonogenic survival (14–16). Besides its well-known antiparasitic effects, chloroquine has incisive intracellular actions that have been widely used in experimental biology for the study of cellular functions (7, 17). In clinical medicine, the inhibition of tumor necrosis factor- α produced by chloroquine (which is highly dependent on phospho-

lipase A₂), together with other immunomodulating effects, has been used for many years to treat patients with chronic autoimmune disorders, such as systemic lupus erythematosus (18, 19).

Chloroquine exhibits an intense affinity for lysosomes (“lysosomotropism”) within the cell metabolism that inhibit the enzymes phospholipase A₂, lysophospholipid acylhydrolase, and monoacylglycerol lipase; these enzymes release arachidonic acid from phospholipids (20–22). The consequence is inhibition of proteolytic processes in lysosomes and blockage of the metabolism of neoglycolipids (14, 23). Through these actions, several molecular signals at the interior of the cell are altered (21, 24–29). Chloroquine also has a strong DNA-intercalating activity (30, 31), which is independent of its lysosomotropism (32–34). Interaction of chloroquine with nucleic acids is incisive and initiates by a fast electrostatic attraction followed by a slow intercalation process (27); this intense binding produces structural perturbations in DNA that render it a poor substrate for endonucleolytic cleavage (8, 27). Chloroquine produces unwinding and relaxation of DNA supercoiling. In this process, 2 different events occur: direct DNA intercalation and inhibition of topoisomerase II, avoiding DNA fragmentation (32, 35, 36). In addition, DNA intercalators bind quadruplex DNA structures at the end of chromosomes inhibiting telomerase, an essential enzyme for the unlimited replicative potential of tumor cells (37). Of interest, despite its intense molecular activity on DNA, genotoxicity of chloroquine is minimal (16).

Figure 2. Magnetic resonance imaging scan of a patient with glioblastoma multiforme treated with chloroquine in addition to surgery, chemotherapy, and radiotherapy.



Top. A large mass is shown on the left hemisphere before treatment. **Bottom.** Forty-four months after the beginning of treatment, no evidence of tumor regrowth is seen. At this time, the patient's Karnofsky performance score was 100 (asymptomatic).

In vitro, chloroquine enters malignant glial cells, blocking the expression of antigenic proteins on their surface. Because of its curtailing action on DNA synthesis and DNA repair processes, chloroquine strongly potentiates the inhibitory effect of radiation on cell multiplication (38, 39). Although chloroquine alone is not cytotoxic, when

associated with ionizing radiation, it produces severe ultrastructural lesions characterized by vacuolization of the endoplasmic reticulum, damage of mitochondria, and an increase of microtubules and microfilaments with subsequent alterations of the cytoskeleton in cultures of carcinoma and melanoma cells (38, 40).

It is also possible that additional intracellular actions of chloroquine may increase the susceptibility of malignant glioma cells to standard therapy. For example, some neoplastic drugs have extended permanence inside cancer cells because of elevation of endosomal and lysosomal pH that increases and maintains the concentration of lipophilic antineoplastic drugs, such as carmustine (21, 36, 41). A conspicuous effect of chloroquine, which has effectively reversed multidrug resistance of cancer cells, is preventing and delaying the outward cell transport of antineoplastic drugs, such as vincristine (36, 42). Finally, the addition of chloroquine to the culture medium of leukemic multidrug-resistant cells decreases resistance to vinblastine by 10- to 15-fold (15, 36, 43–47).

The addition of chloroquine to therapy for glioblastoma multiforme may increase survival at mid-term; however, the long-term prognosis continues to be poor. On the basis of these results, we suggest a large-scale, properly powered, randomized trial to clearly define a potential role for chloroquine in treatment of glioblastoma. Additional modifications to the regimen used in this study could improve our results. The daily dose of chloroquine was mild (150 mg). However, because the intracellular effects of chloroquine are dose-dependent (48), the dose could be selectively increased (for example, to 300 mg/d, which is still fairly well tolerated by humans) in subsequent trials during chemotherapy and radiotherapy; mutagenesis increases and therapy-induced damage of neoplastic cells is maximal at that time (38). Alternatively, chloroquine could be replaced with its analogue, quinacrine, which is more active than chloroquine in some of the cellular functions described previously (8, 10, 18, 42, 49).

From the National Institute of Neurology and Neurosurgery of Mexico.

Acknowledgments: The authors thank Camilo Ríos, PhD, for help with statistical analysis; Roberto Medina, MD, for coding the treatment sets; and Beatriz Cano for monitoring the coded and sealed treatment sets.

Grant Support: By Consejo Nacional de Ciencia y Tecnología (CONACyT) (SALUD-2003-C01-15).

Potential Financial Conflicts of Interest: None disclosed.

Requests for Single Reprints: Julio Sotelo, MD, National Institute of Neurology and Neurosurgery of Mexico, Insurgentes Sur 3877, 14269 Mexico City, Mexico; e-mail, jsotelo@servidor.unam.mx.

Current author addresses and author contributions are available at www.annals.org.

References

- Grossman SA, Batara JF. Current management of glioblastoma multiforme. *Semin Oncol*. 2004;31:635-44. [PMID: 15497116]
- Kanzawa T, Ito H, Kondo Y, Kondo S. Current and future gene therapy for malignant gliomas. *J Biomed Biotechnol*. 2003;2003:25-34. [PMID: 12686720]
- Wasserfallen JB, Ostermann S, Pica A, Mirimanoff RO, Leyvraz S, Villemeure JG, et al. Can we afford to add chemotherapy to radiotherapy for glioblastoma multiforme? Cost-identification analysis of concomitant and adjuvant treatment with temozolomide until patient death. *Cancer*. 2004;101:2098-105. [PMID: 15389472]
- Lopez-Gonzalez MA, Sotelo J. Brain tumors in Mexico: characteristics and prognosis of glioblastoma. *Surg Neurol*. 2000;53:157-62. [PMID: 10713194]
- Souhami L, Seiferheld W, Brachman D, Podgorsak EB, Werner-Wasik M, Lustig R, et al. Randomized comparison of stereotactic radiosurgery followed by conventional radiotherapy with carmustine to conventional radiotherapy with carmustine for patients with glioblastoma multiforme: report of Radiation Therapy Oncology Group 93-05 protocol. *Int J Radiat Oncol Biol Phys*. 2004;60:853-60. [PMID: 15465203]
- Briceño E, Reyes S, Sotelo J. Therapy of glioblastoma multiforme improved by the antimutagenic chloroquine. *Neurosurg Focus*. Accessed at www.aans.org/education/journal/neurosurg/feb03/14-2-3.pdf on 8 June 2005.
- Savarino A, Boelaert JR, Cassone A, Majori G, Cauda R. Effects of chloroquine on viral infections: an old drug against today's diseases? *Lancet Infect Dis*. 2003;3:722-7. [PMID: 14592603]
- Giampietri A, Fioretti MC, Goldin A, Bonmassar E. Drug-mediated antigenic changes in murine leukemia cells: antagonistic effects of quinacrine, an antimutagenic compound. *J Natl Cancer Inst*. 1980;64:297-301. [PMID: 6928222]
- Bennett A, Melhuish PB, Patel S, Randles H, Stamford IF. Cancer in mice: effects of prednisolone or mepacrine alone and with cytotoxic drugs. *Br J Cancer*. 1987;55:385-8. [PMID: 3580263]
- Reyes S, Herrera LA, Ostrosky P, Sotelo J. Quinacrine enhances carmustine therapy of experimental rat glioma. *Neurosurgery*. 2001;49:969-73. [PMID: 11564260]
- Moher D, Jones A, Lepage L. Use of the CONSORT statement and quality of reports of randomized trials: a comparative before-and-after evaluation. *JAMA*. 2001;285:1992-5. [PMID: 11308436]
- National Cancer Institute. Common toxicity criteria. Version 2; 1999. Accessed at www.fda.gov/cder/cancer/toxicityframe.htm on 8 June 2005.
- Stupp R, Mason WP, van den Bent MJ, Weller M, Fisher B, Taphoorn MJ, et al. Radiotherapy plus concomitant and adjuvant temozolomide for glioblastoma. *N Engl J Med*. 2005;352:987-96. [PMID: 15758009]
- Capala J, Carlsson J. Influence of chloroquine and lidocaine on retention and cytotoxic effects of [131I]EGF: studies on cultured glioma cells. *Int J Radiat Biol*. 1991;60:497-510. [PMID: 1679089]
- Weber SM, Levitz SM. Chloroquine interferes with lipopolysaccharide-induced TNF-alpha gene expression by a nonlysosomotropic mechanism. *J Immunol*. 2000;165:1534-40. [PMID: 10903761]
- Riccio ES, Lee PS, Winegar RA, Krogstad DJ, De D, Mirsalis JC. Genetic toxicology testing of the antimalarial drugs chloroquine and a new analog, AQ-13. *Environ Mol Mutagen*. 2001;38:69-79. [PMID: 11473390]
- Itaka K, Yamauchi K, Harada A, Nakamura K, Kawaguchi H, Kataoka K. Polyion complex micelles from plasmid DNA and poly(ethylene glycol)-poly(L-lysine) block copolymer as serum-tolerable polyplex system: physicochemical properties of micelles relevant to gene transfection efficiency. *Biomaterials*. 2003;24:4495-506. [PMID: 12922159]
- Ferrante A, Goh DH. The effect of anti-malarial drugs on human natural killer cells in vitro. *Parasite Immunol*. 1984;6:571-80. [PMID: 6335236]
- Salmeron G, Lipsky PE. Immunosuppressive potential of antimalarials. *Am J Med*. 1983;75:19-24. [PMID: 6603165]
- Nosál R, Jancinová V. Cationic amphiphilic drugs and platelet phospholipase A(2) (cPLA(2)). *Thromb Res*. 2002;105:339-45. [PMID: 12031829]
- Pozzi D, Zompetta C, Faggioni A, Lisi A, De Ros I, Ravagnan G, et al. Early events of fusion between Epstein Barr virus and human lymphoblastoid cells (Raji) detected by R18 fluorescence quenching measurements. *Membr Biochem*. 1990;9:239-51. [PMID: 1967072]
- Kunze H, Hesse B, Bohn E. Effects of antimalarial drugs on several rat-liver lysosomal enzymes involved in phosphatidylethanolamine catabolism. *Biochim Biophys Acta*. 1982;713:112-7. [PMID: 7138892]
- Pacuszka T, Fishman PH. Metabolism of cholesterol, phosphatidylethanolamine and stearylamine analogues of GM1 ganglioside by rat glioma C6 cells. *Biochim Biophys Acta*. 1991;1083:153-60. [PMID: 2036449]
- Hostetler KY, Reasor M, Yazaki PJ. Chloroquine-induced phospholipid fatty liver. Measurement of drug and lipid concentrations in rat liver lysosomes. *J Biol Chem*. 1985;260:215-9. [PMID: 3965448]
- Nielsen FC, Gammeltoft S, Westermarck B, Fahrenkrug J. High affinity receptors for vasoactive intestinal peptide on a human glioma cell line. *Peptides*. 1990;11:1225-31. [PMID: 1965033]
- Law PY, Hom DS, Loh HH. Down-regulation of opiate receptor in neuroblastoma x glioma NG108-15 hybrid cells. Chloroquine promotes accumulation of tritiated enkephalin in the lysosomes. *J Biol Chem*. 1984;259:4096-104. [PMID: 6323457]
- Yin F, Guo M, Yao S. Kinetics of DNA binding with chloroquine phosphate using capacitive sensing method. *Biosens Bioelectron*. 2003;19:297-304. [PMID: 14615086]
- Yeo SJ, Gravis D, Yoon JG, Yi AK. Myeloid differentiation factor 88-dependent transcriptional regulation of cyclooxygenase-2 expression by CpG DNA: role of NF-kappaB and p38. *J Biol Chem*. 2003;278:22563-73. [PMID: 12695520]
- Zhu FG, Reich CF, Pisetsky DS. Effect of cytofectins on the immune response of murine macrophages to mammalian DNA. *Immunology*. 2003;109:255-62. [PMID: 12757621]
- Allison JL, O'Brien RL, Hahn FE. DNA: reaction with chloroquine. *Science*. 1965;149:1111-3. [PMID: 5826527]
- Cohen SN, Yielding KL. Inhibition of DNA and RNA polymerase reactions by chloroquine. *Proc Natl Acad Sci U S A*. 1965;54:521-7. [PMID: 5324393]
- Tchernanenko V, Halvorson HR, Lutter LC. Topological measurement of an A-tract bend angle: variation of duplex winding. *J Mol Biol*. 2003;326:751-60. [PMID: 12581637]
- Snyder RD, Arnone MR. Putative identification of functional interactions between DNA intercalating agents and topoisomerase II using the V79 in vitro micronucleus assay. *Mutat Res*. 2002;503:21-35. [PMID: 12052500]
- Snyder RD. Use of catalytic topoisomerase II inhibitors to probe mechanisms of chemical-induced clastogenicity in Chinese hamster V79 cells. *Environ Mol Mutagen*. 2000;35:13-21. [PMID: 10692223]
- Kaneko T, Mizushima T, Ohtsuka Y, Kurokawa K, Kataoka K, Miki T, et al. Co-induction of DNA relaxation and synthesis of DnaK and GroEL proteins in *Escherichia coli* by expression of LetD (CcdB) protein, an inhibitor of DNA gyrase encoded by the F factor. *Mol Gen Genet*. 1996;250:593-600. [PMID: 8676862]
- Jensen PB, Sørensen BS, Sehested M, Grue P, Demant EJ, Hansen HH. Targeting the cytotoxicity of topoisomerase II-directed epipodophyltoxins to tumor cells in acidic environments. *Cancer Res*. 1994;54:2959-63. [PMID: 8187081]
- Teulade-Fichou MP, Hounsou C, Guittat L, Mergny JL, Alberti P, Carrasco C, et al. Molecular recognition of quadruplex DNA by quinacridine derivatives. *Nucleosides Nucleotides Nucleic Acids*. 2003;22:1483-5. [PMID: 14565448]
- Biller H, Schachtschabel DO, Leising HB, Pfab R, Hess F. [Influence of x-rays and quinacrine (atebrine) or chloroquine (resochine)—alone or in combination—on growth and melanin formation of Harding-Passey melanoma cells in monolayer culture]. *Strahlentherapie*. 1982;158:450-6. [PMID: 7135443]
- Sohn TA, Bansal R, Su GH, Murphy KM, Kern SE. High-throughput measurement of the Tp53 response to anticancer drugs and random compounds using a stably integrated Tp53-responsive luciferase reporter. *Carcinogenesis*. 2002;23:949-57. [PMID: 12082016]
- Pfab R, Schachtschabel DO, Kern HF. [Ultrastructural studies of the effect of x-rays and quinacrine (Atebrin) or chloroquine (Resochin)—alone or in combination—on Harding-Passey melanoma cells in monolayer culture]. *Strahlentherapie*. 1985;161:711-8. [PMID: 4071571]
- Rudling MJ, Collins VP, Peterson CO. Delivery of a clacinomycin A to human glioma cells in vitro by the low-density lipoprotein pathway. *Cancer Res*. 1983;43:4600-5. [PMID: 6309372]
- Inaba M, Maruyama E. Reversal of resistance to vincristine in P388 leukemia by various polycyclic clinical drugs, with a special emphasis on quinacrine. *Cancer Res*. 1988;48:2064-7. [PMID: 3349478]
- Beck WT, Cirtain MC, Glover CJ, Felsted RL, Safa AR. Effects of indole alkaloids on multidrug resistance and labeling of P-glycoprotein by a photoaffinity analog of vinblastine. *Biochem Biophys Res Commun*. 1988;153:959-66. [PMID: 2898941]

44. **Filippov A, Skatova G, Porotikov V, Kobrinsky E, Saxon M.** Ca²⁺-antagonistic properties of phospholipase A2 inhibitors, mepacrine and chloroquine. *Gen Physiol Biophys.* 1989;8:113-8. [PMID: 2777057]
45. **Cho J, Rando RR.** Specific binding of Hoechst 33258 to site 1 thymidylate synthase mRNA. *Nucleic Acids Res.* 2000;28:2158-63. [PMID: 10773086]
46. **Dalpke AH, Opper S, Zimmermann S, Heeg K.** Suppressors of cytokine signaling (SOCS)-1 and SOCS-3 are induced by CpG-DNA and modulate cytokine responses in APCs. *J Immunol.* 2001;166:7082-9. [PMID: 11390452]
47. **Zamora JM, Pearce HL, Beck WT.** Physical-chemical properties shared by compounds that modulate multidrug resistance in human leukemic cells. *Mol Pharmacol.* 1988;33:454-62. [PMID: 3162758]
48. **Hawtrey A, Joubert D, van Jaarsveld P, Pieterse A, van Zyl J, Ariatti M.** Low concentrations of chlorpromazine and related phenothiazines stimulate gene transfer in HeLa cells via receptor-mediated endocytosis. *Drug Deliv.* 2002;9:47-53. [PMID: 11839208]
49. **Bondeson J, Sundler R.** Antimalarial drugs inhibit phospholipase A2 activation and induction of interleukin 1beta and tumor necrosis factor alpha in macrophages: implications for their mode of action in rheumatoid arthritis. *Gen Pharmacol.* 1998;30:357-66. [PMID: 9510087]

Current Author Addresses: Drs. Sotelo, Briceño, and López-González: National Institute of Neurology and Neurosurgery of Mexico, Insurgentes Sur 3877, 14269 Mexico City, Mexico.

Author Contributions: Conception and design: J. Sotelo.
Analysis and interpretation of the data: J. Sotelo.
Drafting of the article: J. Sotelo.
Critical revision of the article for important intellectual content: J. Sotelo, E. Briceño.

Final approval of the article: J. Sotelo, E. Briceño, M.A. López-González.
Provision of study materials or patients: E. Briceño, M.A. López-González.

Statistical expertise: M.A. López-González.

Obtaining of funding: J. Sotelo.

Administrative, technical, or logistic support: J. Sotelo.

Collection and assembly of data: E. Briceño, M.A. López-González.